

Diagnostic performance of ultrasound in detecting early occult scaphoid fractures: A systematic review



Safrizal Rahman^{1*}, Azharuddin¹, Azmi², Rizki Puji Isnanda²,
T. Ichsan², Muhammad Azmi³

ABSTRACT

Background: The diagnosis of scaphoid fractures is further confounded by the fact that up to 16% may be occult on initial plain radiographs. Clinicians have faced a diagnostic dilemma. It is essential to diagnose quickly and accurately, as delayed or missing diagnoses can result in substantial complications. High-frequency ultrasound has emerged as an option for the early detection of occult scaphoid fractures. There are numerous perks to this modality, such as the capacity to conduct dynamic examinations, the absence of ionizing radiation, the relatively low cost, and the broad availability.

Methods: The preferred reporting items for systematic reviews and meta-analyses (PRISMA) was followed for conducting a literature search utilizing PubMed, Cochrane, Science Direct, and Springer Link. The search term “acute occult scaphoid fracture” AND “ultrasound” OR “ultrasonography” was employed. Articles that contained prospective evaluations of the sensitivity and specificity of the use of ultrasonography to diagnose scaphoid fractures were considered.

Results: We have obtained 69 studies, after a full-text review, nine studies are suitable for systematic review. The total sample size was around 572 patients with an average age of 18-41.2. Male patients were higher than female. The article's quality ranged from moderate to high, based on the MINOR Score. Some studies repeated other imaging modalities (plain radiographs, CT Scan, MRI) to validate the ultrasound results. The mean sensitivity was 77.38% (standard deviation of 22.76) and the mean specificity was 84.74% (standard deviation of 14.71).

Conclusion: High-resolution ultrasound performed by experienced operators can achieve sensitivity and specificity comparable to advanced imaging modalities.

Keywords: medicine, orthopaedic, scaphoid fracture, ultrasonography.

Cite This Article: Rahman, S., Azharuddin., Azmi., Isnanda, R.P., Ichsan, T., Azmi, M. 2025. Diagnostic performance of ultrasound in detecting early occult scaphoid fractures: A systematic review. *Physical Therapy Journal of Indonesia* 6(2): 149-154. DOI: 10.51559/ptji.v6i2.313

¹Department of Orthopaedic and Traumatology, Faculty of Medicine, Universitas Syiah Kuala and Dr. Zainoel Abidin Hospital, Banda Aceh, Indonesia;
²Emergency Department, Dr Fauziah Bireuen Hospital, Bireuen, Aceh, Indonesia;
³Department of Radiology, Dr Fauziah Bireuen Hospital, Bireuen, Aceh, Indonesia.

*Corresponding author:

Safrizal Rahman;
Department of Orthopaedic and Traumatology, Faculty of Medicine, Universitas Syiah Kuala and Dr. Zainoel Abidin Hospital, Banda Aceh, Indonesia;
safrizalrahman@usk.ac.id

Received: 2025-04-12

Accepted: 2025-06-20

Published: 2025-07-16

INTRODUCTION

The scaphoid bone is by far the most common target of carpal fractures with an incidence rate of 60–70% and a total of 2-3% of all fractures.^{1,2} The scaphoid, a boat-shaped carpal bone, is in the proximal row of carpal bones, articulating with five other bones: the lunate and capitate medially, the trapezium and trapezoid distally, the radius proximally. Scaphoid injuries and complications are more probable as a result of its intricate anatomy and its distinct blood supply.³

These fractures are most prevalent in young adult males between the ages of 15-30 and they are typically the result of impacts onto an outstretched hand with the wrist in extension and radial deviation.^{1,3,4} This mechanism results in axial loading

through the scaphoid as it impacts against the distal radius, frequently resulting in fractures in the waist of the scaphoid, although proximal pole and distal third fractures may also occur.³

Scaphoid fractures may manifest in a manner that is both subtle and nonspecific. Patients typically describe pain, swelling, and discomfort in the anatomical snuffbox and the scaphoid tubercle.^{3,5} The reliability of clinical procedures, including the scaphoid compression test and Watson's shift test, is variable.⁴ The diagnosis is further confounded by the fact that up to 16% of scaphoid fractures may be occult on initial plain radiographs, even when scaphoid-specific views are obtained.¹ Clinicians have faced a diagnostic dilemma for an extended period of time due to the high prevalence of radiographically

occult fractures. It is essential to diagnose scaphoid fractures quickly and accurately, as delayed or missing diagnoses can result in substantial complications. The scaphoid is at a high risk of avascular necrosis, especially when proximal pole fractures occur, due to its fragile blood supply, which enters distally and flows proximally.³ Non-union, delayed union, pseudoarthrosis, and secondary displacement of the wrist are additional potential complications of untreated scaphoid fractures. It is essential to make an early and accurate diagnosis with the goal to prevent complications such as post-traumatic osteoarthritis, delayed union, nonunion, and avascular necrosis.^{3,5} Wrist immobilization and subsequent imaging after 10-14 days have been the conventional management strategy for suspected scaphoid fractures

with negative initial radiographs.⁴

The American College of Radiology (ACR) recommends utilizing magnetic resonance imaging (MRI) as the initial diagnostic approach for detecting concealed fractures. Nevertheless, some authors contend that the regular utilization of MRI for identifying occult fractures should be avoided because it often leads to excessive diagnosis and treatment. Other approaches with strengths and restrictions in identifying occult fractures also could complement one another. For instance, given its more general availability in smaller centers than MRI despite its radiation penalty, computed tomography (CT) may also substitute for MRI. Though the literature is quite scarce, ultrasound is also becoming more and more popular as a radiation-free, frequently used bedside tool to identify occult fractures. Finally, while nuclear studies or bone scans are exceedingly sensitive, the relative radiation dosage can occasionally be undesirable.²

In the past few years, high-frequency ultrasound has emerged as an option for the early diagnosis of scaphoid fractures. There are numerous perks to this modality, such as the capacity to conduct dynamic examinations, the absence of ionizing radiation, the relatively low cost, and the broad availability. Current high-frequency transducers, which are typically used in the 5-12 MHz range, enable an in-depth examination of the scaphoid cortex and its closest soft tissues.^{3,5} The real-time nature of ultrasound also enables to assess the scaphoid throughout its entire range of motion, resulting in the potential for improving the detection of subtle or partial fractures.⁵

Multiple studies have indicated promising outcomes for using ultrasonography to diagnose scaphoid fractures. The ultrasound criteria for scaphoid fractures usually consist of cortical disintegration, the existence of a hypoechoic hematoma at the fracture site, and radiocarpal effusion.^{3,5} Additionally, certain studies have seen a reduction in the ratio between the scaphoid tubercle and scaphoid waist distances as an extra indication of a fracture.⁵ The sensitivity of ultrasound in early fracture identification may be attributed to its capability to identify indirect symptoms of fracture,

such as soft tissue edema and joint effusion.

Despite these promising findings, the appropriate technique, diagnostic criteria, and overall clinical value of ultrasound for scaphoid fracture diagnosis are still being researched and discussed.^{3,5}

Questions remain about the learning curve for accurate interpretation, the operator experience, and the most effective integration of ultrasound into diagnostic algorithms for suspected scaphoid fractures. It is fascinating to consider the practical role of ultrasound as a screening tool in the emergency department environment, which could reduce the need for unnecessary immobilization and follow-up imaging in some patients. The purpose of this review is to rigorously evaluate the available evidence on the utility of ultrasonography in identifying scaphoid fractures.

METHODS

Search Strategy

A systematic literature review was conducted using the Preferred Reporting Items for Systematic Reviews and Meta-Analyses (PRISMA) guidelines that searched on August 3rd 2024, utilizing PubMed, Cochrane, Science Direct, and Springer Link search engines.⁶ The search term “acute occult scaphoid fracture” AND “ultrasound” OR “ultrasonography” was employed since it was believed to be a wide-ranging, inclusive term. [Figure 1](#) below displays the PRISMA formula diagram. For our review of inclusion criteria, we located 9 journals.

The inclusion and exclusion criteria of this inquiry were described using the PICO (person, intervention, control outcome) technique. It is required that all articles be written in English. Articles that contained prospective evaluations of the sensitivity and specificity of various imaging modalities were considered. Ultrasonography was used to diagnose scaphoid fractures based on radiocarpal effusion (RCE), sapho-trapezium-trapezoid effusion (STTE), and cortical interruption (CI) were included. Articles that did not meet the following criteria were excluded: retrospective research, case reports, biomechanical studies, duplicate results, review articles, and incomplete access to the original article. The papers

were then subjected to a series of screening processes. The title and abstract are screened first, followed by the entire content.

Quality Evaluation

The methodological indicator for non-randomized studies (MINORS) score was utilized to conduct the quality assessment. Because all of the included papers are non-randomized control trial studies. Each of the 12 domains (the first 8 of which are used in non-comparative studies) has a score out of 2, with the optimal scores for non-comparative studies being at least 16 and for comparison studies being at least 24 ([Figure 2](#)).⁷ The investigators discussed scores with a difference of more than two points until they reached an agreement.

RESULTS

After applying the search strategy, a total of 69 studies were found based on the keyword that we used to conduct the search, with 13 of those studies being duplicates. Thirteen papers were kept for full-text evaluation after 43 studies were disqualified because they did not match the inclusion criteria used in the study. We excluded four articles from our systematic review due to a lack of information for sufficient evaluation in the full text, leaving nine studies suitable for inclusion criteria for this review.

This review included a total of nine studies. The articles covered a total of 572 patients, with Individual study sample sizes ranging from 15 to 114 patients, with a mean age of 18 to 41.2 years ([Table 1](#)). The articles' quality ranged from moderate to high, based on the MINOR Score ([Figure 2](#)).

Dacruz, Hodgkinson, Munk, and Senall utilized repeated plain radiographs to corroborate the ultrasound findings. Platon used CT Scan, while Herneth, Yildirim, and Jain used MRI. However, Hauger used no uniformed confirmation test ([Table 2](#)).

Dacruz utilized low low-frequency probe (1 MHz) ultrasound machine and had the lowest sensitivity and specificity (33% and 63% respectively) amongst the others. Hodgkinson used 5 MHz color doppler probe and achieved 100% sensitivity. Hauger also achieved 100%

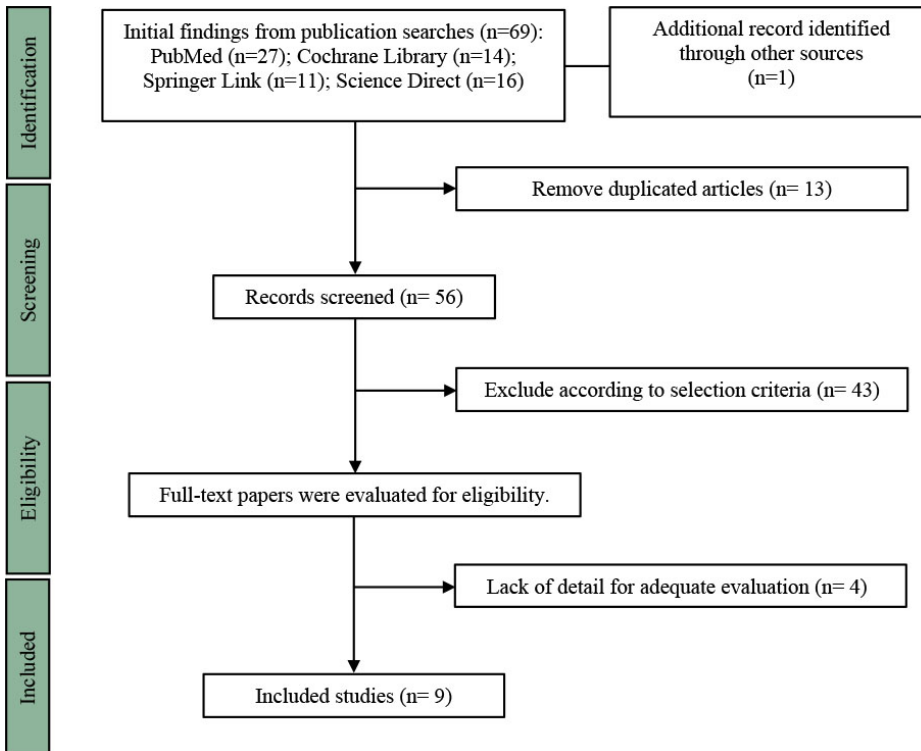


Figure 1. Preferred reporting items for systematic reviews and meta-analyses (PRISMA) flow chart of the study selection process.

by Gibney et al. to have a higher combined sensitivity of 88% and specificity of 99% for the identification of scaphoid fractures.²⁰

The type of ultrasound machine, the proficiency of the operator, the length of the test, and the reference standards all affect how accurately ultrasonography can diagnose hidden scaphoid fractures. High-resolution ultrasound transducers typically outperform traditional ultrasonography. Expert readers consistently show higher sensitivity than novice and intermediate users. The timing of the ultrasound test in relation to the injury may affect accuracy, however studies show that early imaging within 24 hours of damage is equivalent to later time periods. The reference standard used, such as MRI, CT, or follow-up radiographs, can also have an impact on ultrasound's stated diagnostic performance.^{20,21}

Despite its limited diagnostic accuracy, ultrasonography may be useful in examining suspected scaphoid fractures. Ultrasound, a non-ionizing and easily accessible imaging modality, may be conducted at the point of treatment, minimizing the need for further hospital visits and radiation exposure.^{21,22} Ultrasound is especially useful in pediatric groups, pregnant women, and patients who need repeated imaging for fracture reduction.²² Furthermore, ultrasonography may evaluate soft tissue damage, ligaments, and tendons in addition to bone structures.²³

Ultrasonography has the potential to be an alternative or adjunct to radiography for early detection of occult scaphoid fractures. Ultrasound can also differentiate between cortical fracture, hemarthrosis and hematoma. In contrast, CT is excellent for imaging cortical discontinuities and fracture displacements, with reported sensitivities of 72-100% and specificities of 85-100%. MRI is typically regarded as the gold standard, with sensitivity and specificity nearing 100% in many investigations. Bone scintigraphy has a high sensitivity (100%) and specificity (92-98%), however it requires a 3-5 day delay post-injury for best results.²⁴

The use of artificial intelligence (AI) into ultrasonic imaging may improve its diagnostic capabilities. Knight et al. found that an AI model achieved a sensitivity

	Doeruz (1988)	Hedghatton (1993)	Mark (2006)	Herneth (2001)	Huang (2002)	Scapell (2005)	Platon (2011)	Yildirim (2013)	Jan (2018)
1 A clearly stated aim	2	2	2	2	2	2	2	2	2
2 Inclusion of consecutive patients	2	2	2	2	2	2	2	2	2
3 Prospective collection of data	2	2	2	2	2	2	2	2	2
4 Endpoints appropriate to the aim of the study	2	2	2	2	2	2	2	2	2
5 Unbiased assessment of the study endpoint	2	1	2	2	0	2	2	1	1
6 Follow-up period appropriate to the aim of the study	2	2	2	2	2	2	2	2	2
7 Loss to follow-up less than 5%	2	2	1	2	0	0	2	2	2
8 Prospective calculation of the study size	0	0	0	0	0	0	0	0	0
Item 9-12 only for comparative studies									
9 An adequate control group	N/A	N/A	N/A	N/A	N/A	N/A	N/A	N/A	N/A
10 Contemporary groups	N/A	N/A	N/A	N/A	N/A	N/A	N/A	N/A	N/A
11 Baseline equivalence of groups	N/A	N/A	N/A	N/A	N/A	N/A	N/A	N/A	N/A
12 Adequate statistical analyses	N/A	N/A	N/A	N/A	N/A	N/A	N/A	N/A	N/A
Total MINORS score	14	13	13	14	10	12	14	13	13
Maximum possible score	16	16	16	16	16	16	16	16	16

	Poor quality
	Moderate quality
	High quality

Figure 2. Methodological index for non-randomized studies (MINORS) scores.

sensitivity but using higher frequency probe (12 MHz) (Table 3 and Table 4).

DISCUSSION

The scaphoid is the most frequently fractured carpal bone, responsible for 60-70% of carpal fractures, and 11% of hand fractures.¹⁶⁻¹⁹ Nevertheless, the initial radiographs may fail to detect up to 30% of scaphoid fractures, which can lead to a delayed diagnosis and an elevated risk of sequelae, including osteoarthritis,

avascular necrosis, and nonunion.¹⁹ Ultrasonography has emerged as a viable alternative imaging method for early identification of occult scaphoid fractures, however studies have reported varied sensitivity and specificity. Kwee et al. conducted a meta-analysis and discovered that ultrasonography had a pooled sensitivity of 85.6% (95% CI 73.9-92.6%) and specificity of 83.3% (95% CI 72.0-90.6%) for identifying radiographically concealed scaphoid fractures. Cone-beam computed tomography (CBCT) was found

Table 1. Demographics data of included studies

No	Author, year	Methods	Number of Patients	Mean Age	Male/ Female	MINORS
1	Dacruz, 1988 ⁸	Prospective clinical study	111	30	54/57	14
2	Hodgkinson, 1993 ⁹	Prospective clinical study	78	36.8	46/32	13
3	Munk, 2000 ¹⁰	Prospective clinical study	57	38	31/26	13
4	Herneth, 2001 ¹¹	Prospective clinical study	15	23.5	7/8	14
5	Hauger, 2002 ¹²	Prospective clinical study	54	26	35/19	10
6	Senall, 2003 ¹³	Prospective clinical study	18	35	N/A	12
7	Platon, 2011 ¹⁴	Prospective clinical study	62	41.2	29/33	14
8	Yildirim, 2013 ¹⁵	Prospective clinical study	63	>18	N/A	13
9	Jain, 2018 ⁵	Prospective clinical study	114	32	N/A	13

MINORS, methodological indicator for non-randomized studies.

Table 2. Summary of ultrasound features and confirmatory tests

No	Author, year	Baseline	Exam included	Waiting time	Ultrasound device	Confirm test	Ultrasound operator
1	Dacruz, 1988 ⁸	Scaphoid view	CI	Within 7 days	Therasonic Double-5 machine	X-Ray	Senior Physiotherapist
2	Hodgkinson, 1993 ⁹	Scaphoid view	CI	12-72 hours	Acuson 128, 5 MHz	X-Ray	Radiologist
3	Munk, 2000 ¹⁰	Scaphoid view	CI	7 days	Mechanical annular array 7.5 MHz scanner and 5±10 MHz Doppler scanner	X-Ray	MSK Radiologist
4	Herneth, 2001 ¹¹	Scaphoid view	SPE, CI	72 hours	ATL HDI 3000 with 10-5-MHz probe	MRI	Radiologist
5	Hauger, 2002 ¹²	Scaphoid view	SPE, CI	7 days	HDI 3000 and 5000, 12 MHz	X-Ray, CT, MRI, B-Scan	MSK Radiologist
6	Senall, 2003 ¹³	Scaphoid view	SPE, CI	4-7 days	ATL, HDI 3000, 10-5 MHz	X-Ray	MSK Radiologist
7	Platon, 2011 ¹⁴	Scaphoid view	RCE, STTE, CI	3 days	Prosound SSD-5000, 5-13 MHz	CT	Radiologist
8	Yildirim, 2013 ¹⁵	Clinical examination	RCE, STTE, CI	24 hours	DC3, Mindray, 5-13 MHz	MRI	EM doctor
9	Jain, 2018 ⁵	Scaphoid view	CI, RCE	N/A	Linear Array Transducer, 5-12 MHz	MRI	Radiologist

B-Scan, brightness scan; CI, cortical interruption; CT, computed tomography; EM, emergency medicine; MHz, Megahertz; MRI, magnetic resonance imaging; MSK, musculoskeletal; N/A, not available; RCE, radiocarpal effusion; STTE, sapho-trapezium-trapezoid effusion.

of 91% and 100% for detecting scaphoid fractures on 2D and 3D ultrasound images, respectively, comparable to expert human readers. The development of portable, low-cost ultrasound transducers and app-based AI interpretation could increase the accessibility and reliability of ultrasound for scaphoid fracture diagnosis.²¹

The diagnostic accuracy of ultrasound is not consistent in detecting occult scaphoid fractures as it depends on factors like equipment used, operator skill, timing of examination and reference standards. However, ultrasound offers a number of advantages over MRI which include

ease of access to the technology, cost effectiveness as well as evaluation of soft tissue structures.²⁵

Although MRI has outstanding sensitivity and specificity, it is limited by its high cost, restricted accessibility, and the likelihood of false-positive results. In terms of specificity and evaluating fracture characteristics CT is good but it may not be so good as regards sensitivity for non-displaced fractures. The exact role of ultrasound in diagnosing suspected scaphoid fractures is still under discussion. Nevertheless, even though some researchers suggest that use of ultrasounds

as a first step in triaging emergencies or when MRI/CT are not available, large-scale clinical trials have failed to provide enough evidence in favor of this approach at a global level yet. The reason why there is no consensus on how patients should be diagnosed with suspected scaphoid fractures revolves around several inherent hurdles: low prevalence rate of actual fractures among suspected ones and the absence of universally accepted gold standard for diagnosis. These factors make it challenging to evaluate the diagnostic performance of any individual imaging modality accurately.²⁵

Table 3. Sensitivities and specificities of ultrasound from other imaging modalities

No	Author, year	Sensitivities	Specificities	PPV	NPV
1	Dacruz, 1988 ⁸	33%	63%	4.80%	94.29%
2	Hodgkinson, 1993 ⁹	100%	74%	41.4%	100%
3	Munk, 2000 ¹⁰	50%	91%	56%	90%
4	Herneth, 2001 ¹¹	78%	100%	100%	75%
5	Hauger, 2002 ¹²	100%	98%	83%	100%
6	Senall, 2003 ¹³	78%	89%	88%	80%
7	Platon, 2011 ¹⁴	92%	71%	46%	97%
8	Yildirim, 2013 ¹⁵	85,7%	100%	100%	100%
9	Jain, 2018 ⁵	79.76%	76.67%	90.54%	57.5%

NPV, negative predictive value; PPV, positive predictive value.

Table 4. Statistic description

No	Variable	N	Minimum	Maximum	Mean	Standard deviation
1	Sensitivities	9	33%	100%	77.38%	22.76%
2	Specificities	9	63%	100%	84.74%	14.71%
3	PPV	9	4.80%	100%	67.75%	31.95%
4	NPV	9	57.5%	100%	88.20%	13.95%

N, number of articles

Ultrasonography could potentially offer an alternative to radiographic examination for early diagnosis of occult scaphoid fractures. The existing information shows that ultrasonography, especially when administered by skilled operators with high-resolution equipment, can achieve reasonably high sensitivity and specificity. There is need to watch out for differences in diagnostic accuracy which may be attributed to factors such as the quality of ultrasound equipment, operator skills, timing of examination and reference standard. In order to enhance the utility of ultrasonography in the diagnosis of occult scaphoid fractures, several areas that need further research should be focused on. The primary objective should be the standardization of ultrasonography techniques and determination of the best time for testing so as to reduce variability and improve diagnostic accuracy. Additionally, more prospective studies are necessary before proving beyond any reasonable doubt that ultrasonography can be used reliably for diagnosing hidden scaphoid fractures including its impact on patient outcomes and healthcare costs.

Third, further research is needed on the usefulness of ultrasound in addressing unusual injuries, such as bilateral scaphoid fractures, in order to produce evidence-based diagnostic and treatment

guidelines. Finally, the integration of AI with ultrasound imaging is a promising advance that deserves more investigation, as it has the potential to improve diagnostic accuracy and accessibility, particularly in resource-constrained environments. Addressing these information gaps might make ultrasonography a viable tool for early identification and treatment of occult scaphoid fractures, thereby enhancing patient care.

CONCLUSION

Despite significant fluctuation in diagnostic accuracy, skilled operators may conduct high-resolution ultrasound with sensitivity and specificity equivalent to modern imaging modalities. The use of artificial intelligence in ultrasonic imaging may improve diagnostic capabilities and accessibility. However, method consistency, appropriate examination time, and large-scale prospective investigations are required to evaluate and compare the significance of ultrasonography in treating scaphoid fractures with current diagnostic routes.

CONFLICT OF INTEREST

All author declares there is no conflict of interest regarding publication of the study.

FUNDING

None.

AUTHOR CONTRIBUTIONS

SR, conceived the study design; SR, A, A, RPI, TI, MA contributed in manuscript writing and agreed upon final version of manuscript for publication.

ETHICAL CONSIDERATION

Not mandatory in systematic review.

REFERENCES

- Mallee WH, Wang J, Poolman RW, Kloen P, Maas M, de Vet HC, Doornberg JN. Computed tomography versus magnetic resonance imaging versus bone scintigraphy for clinically suspected scaphoid fractures in patients with negative plain radiographs. *Cochrane Database of Systematic Reviews*. 2015(6).
- Jorisaal P, Sulay CB, Octavius GS. An umbrella review and updated meta-analysis of imaging modalities in occult scaphoid and hip and femoral fractures. *Journal of Clinical Medicine*. 2024 Jun 27;13(13):3769.
- Ortiz AF, Guevara SZ, Ramírez SM, Rojas JC, Malo RG, Beaujon LF, Ochoa MM, Zarate JF, Niño MF, Aguilar MO. What is the role of ultrasonography in the early diagnosis of scaphoid fractures?. *European Journal of Radiology Open*. 2021 Jan 1;8:100358.
- Bäcker HC, Wu CH, Strauch RJ. Systematic review of diagnosis of clinically suspected scaphoid fractures. *Journal of wrist surgery*. 2020 Feb;9(01):081-9.

5. Jain R, Jain N, Sheikh T, Yadav C. Early scaphoid fractures are better diagnosed with ultrasonography than X-rays: A prospective study over 114 patients. *Chinese Journal of Traumatology*. 2018 Aug 1;21(04):206-10.
6. Page MJ, McKenzie JE, Bossuyt PM, Boutron I, Hoffmann TC, Mulrow CD, Shamseer L, Tetzlaff JM, Akl EA, Brennan SE, Chou R. The PRISMA 2020 statement: an updated guideline for reporting systematic reviews. *BMJ*. 2021 Mar 29;372.
7. Ma LL, Wang YY, Yang ZH, Huang D, Weng H, Zeng XT. Methodological quality (risk of bias) assessment tools for primary and secondary medical studies: what are they and which is better?. *Military Medical Research*. 2020 Feb 29;7(1):7.
8. DaCruz DJ, Taylor RH, Savage B, Bodiwala GG. Ultrasound assessment of the suspected scaphoid fracture. *Emergency Medicine Journal*. 1988 Jun 1;5(2):97-100.
9. Hodgkinson DW, Nicholson DA, Stewart G, Sheridan M, Hughes P. Scaphoid fracture: a new method of assessment. *Clinical radiology*. 1993 Dec 1;48(6):398-401.
10. Munk B, Bolvig L, Krøner K, Christiansen T, Borris L, Boe S. Ultrasound for diagnosis of scaphoid fractures. *The Journal of Hand Surgery: British & European Volume*. 2000 Aug 1;25(4):369-71.
11. Herneth AM, Siegmeth A, Bader TR, Ba-Ssalamah A, Lechner G, Metz VM, Grabenwoeger F. Scaphoid fractures: evaluation with high-spatial-resolution US—initial results. *Radiology*. 2001 Jul;220(1):231-5.
12. Hauger O, Bonnefoy O, Moinard M, Bersani D, Diard F. Occult fractures of the waist of the scaphoid: early diagnosis by high-spatial-resolution sonography. *American journal of Roentgenology*. 2002 May;178(5):1239-45.
13. Senall JA, Failla JM, Bouffard JA, van Holsbeeck M. Ultrasound for the early diagnosis of clinically suspected scaphoid fracture. *The Journal of hand surgery*. 2004 May 1;29(3):400-5.
14. Platon A, Poletti PA, Van Aaken J, Fusetti C, Della Santa D, Beaulieu JY, Becker CD. Occult fractures of the scaphoid: the role of ultrasonography in the emergency department. *Skeletal radiology*. 2011 Jul;40(7):869-75.
15. Yildirim A, Unluer EE, Vandenberg N, Karagoz A. The role of bedside ultrasonography for occult scaphoid fractures in the emergency department. *Ulus Travma Acil Cerrahi Derg*. 2013 May 1;19(3):241-5.
16. Karl JW, Swart E, Strauch RJ. Diagnosis of occult scaphoid fractures: a cost-effectiveness analysis. *JBJS*. 2015 Nov 18;97(22):1860-8.
17. Brößner P, Hohlmann B, Welle K, Radermacher K. Validation of Automated Ultrasound-based Registration for Navigated Scaphoid Fixation: Evaluation of registration performance regarding simulated screw placement. *In Current Directions in Biomedical Engineering* 2021 Aug 1;7(1):116-20.
18. Broessner P, Hohlmann B, Radermacher K. Ultrasound-based navigation of scaphoid fracture surgery. *In Bildverarbeitung für die Medizin 2021: Proceedings, German Workshop on Medical Image Computing, Regensburg, March 7-9, 2021* 2021 Feb 27 (pp. 28-33). Wiesbaden: Springer Fachmedien Wiesbaden.
19. Simón FP, Medrano BG, Serrano PJ. Diagnostic and Therapeutic Approach to Acute Scaphoid Fractures. *Revista Iberoamericana de Cirugía de la Mano*. 2020 Nov;48(02):109-18.
20. Yang TW, Lin YY, Hsu SC, Chu KC, Hsiao CW, Hsu CW, Bai CH, Chang CK, Hsu YP. Diagnostic performance of cone-beam computed tomography for scaphoid fractures: a systematic review and diagnostic meta-analysis. *Scientific Reports*. 2021 Jan 28;11(1):2587.
21. Knight J, Zhou Y, Keen C, Hareendranathan AR, Alves-Pereira F, Ghasseminia S, Wichuk S, Brilz A, Kirschner D, Jaremko J. 2D/3D ultrasound diagnosis of pediatric distal radius fractures by human readers vs artificial intelligence. *Scientific Reports*. 2023 Sep 4;13(1):14535.
22. Jacob R, Stoicescu ER, Cerbu S, Jacob D, Amaricai E, Catan L, Belei O, Iacob ER. Could ultrasound be used as a triage tool in diagnosing fractures in children? a literature review. *In Healthcare* 2022 Apr 29;10(5):823.
23. Russo A, Reginelli A, Lacasella GV, Grassi E, Karaboue MA, Quarto T, Busetto GM, Aliprandi A, Grassi R, Berritto D. Clinical application of ultra-high-frequency ultrasound. *Journal of Personalized Medicine*. 2022 Oct 19;12(10):1733.
24. Clementson M, Björkman A, Thomsen NO. Acute scaphoid fractures: guidelines for diagnosis and treatment. *EFORT open reviews*. 2020 Feb 3;5(2):96-103.
25. Stirling PH, Strelzow JA, Doornberg JN, White TO, McQueen MM, Duckworth AD. Diagnosis of suspected scaphoid fractures. *JBJS reviews*. 2021 Dec 1;9(12):e20.



This work is licensed under a Creative Commons Attribution